ISSN: 2322 - 0902 (P)
ISSN: 2322 - 0910 (O)

International Journal of Ayurveda and Pharma Research

Case Study

AYURVEDIC MANAGEMENT OF CLOSED GLOBE INJURY

Anagha T[1]*, V.K.V. Balakrishnan[2]

*[1]PG Scholar, [2]Professor & HOD, Dept. of Shalakya Tantra, Government Ayurveda College, Kannur, Kerala, India.

Article info

Article History:
Received: 16-08-2026
Accepted: 26-09-2026
Published: 04-10-2026

KEYWORDS:
Closed Globe Injury, *Nayanabhighata*, Ocular trauma.

ABSTRACT

Closed globe injury is a form of blunt ocular trauma without a full-thickness wound of the eyewall. Contusional injuries may vary in severity from a simple corneal abrasion to an extensive intraocular damage. Berlin's edema (commotio retinae) is a retinal manifestation of blunt trauma associated with visual disturbance. In Ayurveda, traumatic ocular disorders are described under *Nayanabhighata Pratishedha Adhyaya* of *Susrutha Samhitha Uttara Tantra*. A 37-year-old male presented with pain, redness, watering and blurring of vision in the left eye two days after blunt trauma from a wooden branch while travelling on a motorcycle. Examination showed subconjunctival hemorrhage, anterior uveitis, retinal edema involving the superior, inferior and temporal retina and Berlin's edema. A multimodal Ayurvedic intervention was administered, comprising internal medicines and external therapies. Following treatment distant visual acuity improved from 6/9 to 6/6 and near vision from N10 to N6. Pain, redness, watering, subconjunctival hemorhage, congestion and visual disturbance resolved. Follow-up OCT demonstrated restoration of normal foveal contour with near-complete resolution of retinal edema. This case documents clinical and visual improvement following multimodal Ayurvedic management. However, a single case cannot establish treatment efficacy or causality, and further controlled clinical studies are required.

INTRODUCTION

The eye is a highly specialized sensory organ, and preservation of vision is fundamental to an individual's daily functioning and quality of life. Ocular trauma is an important cause of visual morbidity and can affect almost any ocular structure, with clinical manifestations ranging from superficial anterior segment injuries to potentially sight-threatening posterior segment involvement. The nature and severity of the resultant damage are influenced by factors such as the mechanism and force of trauma, its site of impact, and the ocular tissues involved.

From the contemporary ophthalmological perspective, mechanical injuries to the eye are classified according to the integrity of the ocular wall. The Birmingham Eye Trauma Terminology (BETT) categorizes these injuries into open-globe and closed-globe injuries.[1]

Access this article online

Quick Response Code

https://doi.org/10.47070/ijapr.v14i9.4381

Published by Mahadev Publications (Regd.) publication licensed under a Creative Commons Attribution-NonCommercial-ShareAlike 4.0 International (CC BY-NC-SA 4.0)

A closed-globe injury is characterized by the absence of a full-thickness wound of the cornea or sclera, while an open-globe injury involves a full-thickness defect in the eyewall. Closed-globe injuries include contusion and lamellar laceration and are commonly encountered following blunt trauma. Despite the preservation of the external integrity of the globe, such injuries may involve deeper ocular structures and produce significant visual consequences.

Blunt ocular trauma presents with a varied clinical spectrum. Trauma that appears relatively minor externally may cause damage to structures such as the anterior chamber, iris, lens, choroid and retina. Hence, the absence of an obvious penetrating wound does not exclude clinically significant intraocular damage. Careful ophthalmic evaluation and timely intervention are therefore essential for identifying the extent of injury and minimizing the risk of lasting visual impairment.

In Ayurveda, injuries involving the eye are described under the concept of *Nayanabhighata*. Acharya Sushruta has devoted a specific chapter, *Nayanabhighata-Pratishedha*, in *Uttara Tantra* to the

management of ocular injuries.[2] The classical description recognizes various manifestations following ocular trauma, including *Samrambha*, *Raga* and *Tumula ruja*, reflecting inflammatory changes, redness and severe pain respectively. Sushruta also describes therapeutic measures such as *Nasya, Alepa, Parisheka* and *Tarpana* in the management of traumatic ocular conditions, emphasizing appropriate care according to the clinical presentation and extent of injury. The classical description of *Nayanabhighata* reflects a systematic Ayurvedic approach to ocular trauma, with emphasis on recognition of clinical manifestations, assessment of the affected ocular structures and selection of appropriate therapeutic measures.

Case Report

A 37-year-old male presented to the outpatient department with complaints involving the left eye. The patient sustained blunt trauma to the left eye on 21 February 2026 when a wooden branch struck the eye while he was travelling on a motorcycle. He presented for Ayurvedic management on 23 February 2026, two days after the injury. The presenting complaints were pain, redness, watering and blurring of vision in the affected eye.

Medical History

Following the trauma, the patient consulted an allopathic hospital on the day of accident, received treatment with oral antibiotics, topical antibiotics and steroids, including a combination of moxifloxacin and dexamethasone eye drops, homatropine eye drops, and moxifloxacin ophthalmic ointment. The medicines were taken only for one day. CT brain examination performed on 22 February 2026 was reported as showing no abnormality.

General Examination

Patient had no other major injury, no vomiting, and no unconsciousness after accident.

Pulse rate - 80/minute

Respiratory rate – 18/minute

BP - 130/80 mmHg.

Clinical Findings

Parameter	Right Eye	Left Eye
Visual acuity	6/6	6/9
Near vision	N6	N10
Intraocular pressure	12 mmHg	13 mmHg
External examination	Normal	Abrasion over left eyebrow (0.5 × 0.1 × 0.1 cm); abrasion below left upper eyelid (0.1 × 0.1 × 0.1 cm); upper eyelid edema
Anterior segment	Normal	Subconjunctival hemorrhage; no corneal abrasion (fluorescein stain negative); anterior uveitis (SUN grading Grade 1); dilated pupil (prior Homatropine use)
Posterior segment	Normal	Berlin's edema; retinal edema involving superior, inferior and temporal retina; cup-disc ratio 0.4; vessels normal
Extraocular movements	Full	Full
RAPD	Absent	Absent

Diagnostic Assessment

The clinical diagnosis was *Nayanabhighataja Netraroga* corresponding to closed globe injury, with associated subconjunctival hemorrhage, anterior uveitis, retinal edema and Berlin's edema. The Ayurvedic diagnostic framework considered the presentation under *Nayanabhighata*, with management principally following *Pitta-Rakta Abhishyanda Chikitsa.*

Therapeutic Intervention

The initial treatment was administered for five days and consisted of the following internal and external interventions:

S.No.	Intervention	Dose/Frequency	Route/Duration
1	*Guluchyadi Kashayam*	90 ml, twice daily	Before food
2	*Chandraprabha Vati*	1 tablet, twice daily	Before food
3	*Avipathy Choornam*	1 tsp at bedtime	With hot water
4	*Patoladi Ghritam*	1 tsp, twice daily	Before food
5	*Laksha Guggulu*	1 tablet, twice daily	After food
6	*Yashti Kashaya Seka*	4 times daily	External
7	*Bidalaka* with *Mukkadi Purampada*	6 times daily	External

8	*Aschyotana* with *Sarkara, Masthu* and *Kshoudra*	6 times daily	Eye drops
9	*Takradhara*	—	5 days
10	*Shirovadana Lepa* with *Mukkadi* and *Saribadi Choorna*	—	5 days

Follow-up and Outcomes

Outcome measure	**Change documented**
Pain	Resolved
Redness	Resolved
Watering	Resolved
Congestion	Resolved
Visual disturbance	Resolved
Subconjunctival hemorrhage	Resolved
Retinal edema	Near-complete resolution
Visual acuity, left eye	6/9 → 6/6
Near vision, left eye	N10 → N6
OCT	Restoration of normal foveal contour with near-complete resolution of retinal edema

Timeline

Date	**Clinical event**
21 February 2026	Blunt trauma to the left eye from a wooden branch while travelling on a motorcycle
22 February 2026	CT brain performed; no abnormality reported.
23 February 2026	OPD presentation; Ayurvedic treatment initiated.
27 February 2026	50% reduction in Subconjunctival hemorrhage, AC - Quiet
28 February 2026	Pain, watering resolved. Discharged.
1 March 2026	Subconjunctival hemorrhage resolved, conjunctival congestion present
6 March 2026	Congestion reduced
13 March 2026	*Jalookavacharana* performed over the left periocular region.
26 March 2026	Final review: visual acuity 6/6, near vision N6; OCT improved with near-complete resolution of retinal edema.



23/2/26



27//2/26

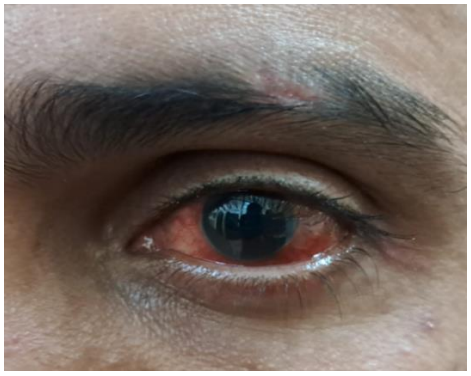

6/3/26

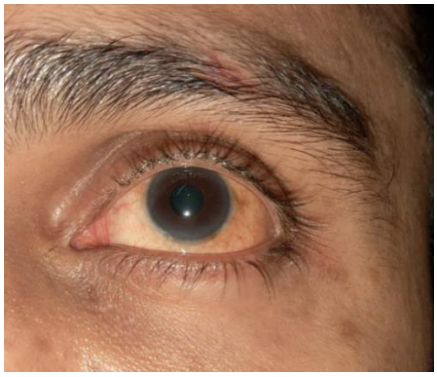

13/3/26

DISCUSSION

The treatment protocol in the present case was planned based on the Ayurvedic understanding of *Nayanabhighata*, with emphasis on *Pitta-Rakta shamana*, reduction of *Shotha*, *Raga* and *Ruja*, and local soothing of the injured eye. Both internal and external therapies were employed according to the clinical manifestations.

Guluchyadi Kashaya contains predominantly bitter and cooling drugs and is employed in conditions associated with *Pitta* and inflammatory manifestations. It is also carminative in action. *Chandraprabha Vati* contains 37 ingredients including *Guggulu* and *Shilajitu* and have *Katu tikta rasa* and *Laghu ruksha guna.* It is indicated in *Netraroga*. *Avipatti Choorna* is a *Pitta-shamaka* and *Anulomana* formulation, with *Trivrit* as an important constituent. *Patoladi Ghrita* is described in *Ashtanga Hridaya Drishti roga chikitsa* in the management of disorders involving *Pitta* and *Rakta*, with relevance to diseases affecting the eye and other sense organs. *Laksha Guggulu* was incorporated as a supportive formulation following traumatic injury to facilitate tissue repair.

Yashti Kashaya Seka was performed to reduce the local irritation and inflammation and provide a cooling and soothing effect to the affected eye owing to the *Pitta rakta hara* and *Sheeta* properties of *Yashtimadhu. Bidalaka* with *Mukkadi Purampada* was intended to reduce the local swelling and redness and curb the inflammatory pathology.

Aschyotana with *Sarkara, Masthu and Kshoudra* is specifically mentioned in *Arjuna chikitsa* by *Acharya Vagbhata.*[3] *Takradhara* helped in the nourishment of the retinal tissues and reducing retinal edema, thereby potentially maintaining retinal integrity. *Shirovadana Lepa* with *Mukkadi* and *Saribadi Choorna* also have *Sothahara* action and reduce the inflammation due to its *Sheetha* and *Pittakapha hara* action.

Rakta Mokshana through *Jalooka Avacharana* was performed once. Leech saliva contains biologically active substances, including anticoagulant and anti-inflammatory components, which may facilitate local blood flow and modulate inflammatory responses.

Thus, the overall treatment strategy combined systemic and local approaches, primarily targeting *Pitta-Rakta* involvement and inflammatory manifestations associated with *Nayanabhighata*. The therapeutic protocol can be viewed as a multimodal application of classical Ayurvedic principles rather than the action of a single formulation. However, as this is a single case, the observed improvement cannot be attributed to any individual medicine, and further controlled clinical studies are required to establish the specific contribution of these interventions.

CONCLUSION

This case documents the clinical course of a closed globe injury managed using a multimodal Ayurvedic intervention. Improvement was observed in symptoms, visual acuity and near vision, with near-complete resolution of retinal edema and restoration of normal foveal contour on follow-up OCT. Although the outcome is favorable, evidence from a single case is insufficient to establish treatment efficacy or causality. Well-designed clinical studies with appropriate controls, standardized outcome measures and longer follow-up are warranted.

Patient Perspective

The patient reported satisfaction with the treatment outcome. No discomfort or significant adverse effects were experienced during treatment.

Informed Consent

Written informed consent was obtained from the patient for treatment, clinical photography, and publication of this case report.

REFERENCES

1. Kaur K, Gurnani B. Clinical review- Closed globe injury. 2023.
2. Susruta Samhita. Sharma PV, translator. Vol. 3. Varanasi: Chaukhambha Visvabharati; 2005. p. 179.
3. Vagbhata. Ashtanga Hridayam. Murthy KR Srikantha, translator. 8th ed. Vol. 3. Varanasi: Chowkhamba Krishnadas Academy; 2015. p. 97.

Cite this article as:
Anagha T, V.K.V. Balakrishnan. Ayurvedic Management of Closed Globe Injury. International Journal of Ayurveda and Pharma Research. 2026;14(9):156-159.
https://doi.org/10.47070/ijapr.v14i9.4381
Source of support: Nil, Conflict of interest: None Declared

***Address for correspondence**
Dr. Anagha T
PG Scholar,
Dept. of Shalakya Tantra,
Government Ayurveda College,
Kannur, Kerala
Email: anagha14.97@gmail.com

Disclaimer: IJAPR is solely owned by Mahadev Publications - dedicated to publish quality research, while every effort has been taken to verify the accuracy of the content published in our Journal. IJAPR cannot accept any responsibility or liability for the articles content which are published. The views expressed in articles by our contributing authors are not necessarily those of IJAPR editor or editorial board members.