



Case Study

AN AYURVEDA APPROACH IN THE MANAGEMENT OF CENTRAL SEROUS CHORIORETINOPATHY - A CASE STUDY

Meera Panigrahi^{1*}, Naveen B S², Ajoy Viswam³, Krishnan Namboodiri G⁴

¹PG Scholar, ²Professor, ³Assistant Professor, ⁴Assistant Professor, Department of Shalaky Tantra, Sri Sri College of Ayurveda Science and Research, Bangalore.

Article info

Article History:

Received: 17-09-2021
Revised : 25-09-2021
Accepted: 12-10-2021
Published: 07-11-2021

KEYWORDS:

Timira, Central Serous Chorioretinopathy, *Dristi gata Roga*, Case Report, Ayurveda Management

ABSTRACT

Central Serous Chorioretinopathy (CSC) is one among the retinal disorder and a condition having high recurrence rate relatively; etiology and pathogenesis of which remains indeterminate. The effects on the retina are usually self-limited, although some people are left with permanent vision loss due to progressive and irreversible photoreceptor damage or retinal pigment epithelium atrophy. There have been a number of interventions used in CSC, including laser treatment, photodynamic therapy (PDT), intravitreal injection of anti-vascular endothelial growth factor agents, and sub threshold lasers. In *Ayurveda* the signs and symptoms of this can be considered under 1st and 2nd *Patalagata Timira* which described under *Dristi gata Roga* in all classics of Ayurveda. Pathogenesis suggests involvement of *Pitta* and *Kapha dosha* mainly. Therefore a treatment attempt was planned in the lines of *Pitta Kapha shamana*. After the treatment the quality of vision had been showed significant improvement. Foveal thickness and macular volume in OCT findings also showed significant reduction. The present paper discusses a case study of CSC and its Ayurveda Treatment.

INTRODUCTION

Central Serous Chorioretinopathy (CSC) is an idiopathic disorder mostly affects a middle age person in unilateral eye. Annual incidence of CSC to be 9.9 per 100,000 men and 1.7 per 10,000 women in a population. Incidence of bilateral CSC is more in Asians. CSC is said to occur six times more commonly in men compared with women. Most acute CSC cases resolve spontaneously within 2-3 months. Prognosis is highly dependent on presenting visual acuity; patients with initial visual acuities of 6/6 remain at that level, while patients with initial visual acuities of less than 6/9 recover on average two to three Snellen lines over the next few years [2].

Men are more likely to develop this condition as compared to women. It is a serous detachment of the neurosensory retina and/or the retinal pigmented epithelium (RPE) in the posterior pole. The condition allows choroidal fluid to leak beneath retina. The buildup of fluid can occur due to small breaks in retinal pigment epithelium [1], [5].

The etiology of CSC is unknown, but several mechanisms are believed to play a role. The most widely accepted mechanism is hyper permeability of the choroid. The other possible mechanism is breakdown of the RPE pumps leading to a disruption in the zona adherens between the RPE cells. This results in a breakdown of the blood retinal barrier and subsequent leakage of plasma into the retina. The paper makes a short discussion to evaluate choroidal and retinal changes before and after Ayurveda management [6].

Symptoms of Central Serous Chorioretinopathy can include distorted, dimmed or blurred central vision [4]. A dark area will appear in central vision. A white object may appear to have a brownish tinge or appear duller in color and floaters[8]. Over 90% of patients regain vision within 6 months of manifestation. Some visual abnormality can remain even if visual acuity is normal. Lasting problem can include decreased night vision, colour discrimination problems, and some distortion. There have been a number of interventions used in CSC, including laser treatment, photodynamic therapy (PDT), intravitreal injection of anti-vascular endothelial growth factor agents, and sub threshold lasers [1].

Access this article online

Quick Response Code



<https://doi.org/10.47070/ijapr.v9iSuppl1.2048>

Published by Mahadev Publications (Regd.)
publication licensed under a Creative Commons
Attribution-NonCommercial-ShareAlike 4.0
International (CC BY-NC-SA 4.0)

In 1st *Patala* the vision becomes *Avyakta*, which can be considered as blurred, distorted vision and in 2nd *Patala* vision reduces further and patient sees the objects as if covered by cloud, *Makhsika Mashakan Pashyat* which can be considered as floaters. So the condition can be correlated to 1st and 2nd *Patala gata Timira* in Ayurveda [3]. Edema in Macula, is caused by exudation from parafoveal or choroidal capillaries. This is a classical feature of *Vimarga Gamana* from *Rasavaha* and *Raktavaha Srotas*. The transient nature of the condition is suggestive of *Saadhyavyadhi*. Considered all above points in mind a case study was done on Central Serous Chorioretinopathy (CSC).

AIMS AND OBJECTIVES

To study the efficacy of Ayurveda management in Central Serous Chorioretinopathy.

MATERIALS AND METHODS

Case Report

Material: A case of central Serous Chorioretinopathy visited to Shalakya Tantra OPD, Sri Sri College of Ayurvedic Science and Research, Bengaluru.

Chief complaints

A moderately built female patient aged 38 yrs reported to the office) with chief complain of blurred vision for both near and far objects, since 2 month and Floaters since 4 weeks.

History of presenting complaint

Vision of Patient was said to be apparently normal before 2 months. One day when she was at home, she noticed a sudden onset of smoky blurry and distorted vision in her left eye. Her central vision was primarily affected initially. Followed by floaters which aggravated in the evenings. Then she visited an eye hospital, where she was advised to go for OCT and prescribed steroidal drops, the details of which were not available. She followed the prescription for one month but found no relief. She did not want to use the steroidal drop further. Then she visited our OPD and after examination of fundus and analyzing the OCT reports it was diagnosed as Central Serous Chorioretinopathy.

Past history

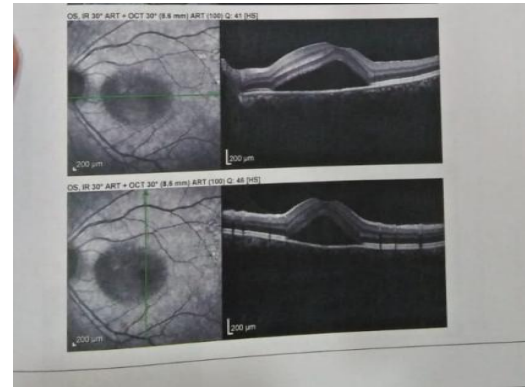
No relevant past history was noted.

Treatment history

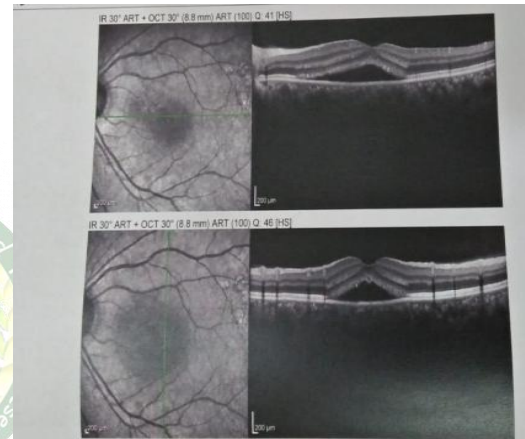
Ophthalmologist initially had prescribed tropical steroids; which she continued for 1 month. Pt had no history of refractive error till date.

Investigation

OCT reports reviled serous detachment of retina with no retinal tear.



Pic 1: OCT before treatment



Pic 2: OCT after treatment

Systemic examination- all systemic examinations were carried out and found to be normal.

Netra pariksha- ocular examination

External ocular examination- all external ocular examinations were carried out and found to be normal. Confrontation test- normal.

Colour vision test- patient could identify the colour of all the plates in Ishihara color plates. (indicating normal colour vision).

Fundus examination

Right Eye- Normal with no changes in the red glow, Normal CD ratio i.e. <0.5.

Left Eye- Dull fundus with normal CD ratio i.e. <0.5.

Visual Acuity

Table 1: Visual Acuity: Before and After Treatment

Visual Acuity	Before Treatment		After Treatment	
	DV	NV	DV	NV
BE	6/6p	N6p	6/6	N6
RE	6/6	N6p	6/6	N6
LE	6/12	N6p	6/6p	N6

MANAGEMENT**In first visit**

Treatment was initiated with *Deepana Pachana* using *Hingwashtaka choorna* 1tsp Three times per day with the 1st bolus of food for five days

- *Snehapana* with *Maha Tiktaka Ghrita*- Three days, 30ml- 60ml- 90ml. By the end of these three days patient attained *Samyak Snigdha Lakshana*. Then followed by *Abhyanga* and *Swedana*.
- *Virechana* with *Trivrut Lehya*- 50gm (no. of Vegas observed - 9)
- *Samsarjanakarma* was advised and patient was asked to take *kanji* made out of brown rice one part and water fourteen parts for four *Annakalas*[7].
- *Takra Dhara* for Seven days.
After Seven days the second set of treatment was given.

In second visit

- *Nasya- Gudardraka Nasya* for three days followed by *Ksheera bala* 101 for four days.
- *Tarpana - Ashwagandha Ghrita*, Five days.
- *Seka- Yashtimadhu Ksheerapaka + Saindhava*, Seven days.
- *Pindi- Triphala Pindi*, Seven days.

Adverse Reactions:No adverse reactions found during the course of treatments.

Advise on discharge

- *Punarnava Kashaya*- 20 ml twice daily before food with equal quantity of warm water.
- *Ashwagandha Ghrita*- ½ tsp at bed time with half cup of warm water
- *Triphala choorna*- 5gm before bed daily with luke warm water.

* for 1 month

RESULT

There was significant improvement in visual acuity and OCT report of both eyes.

DISCUSSION

Central Serous Chorioretinopathy is a condition can be considered under 1st and 2nd *Patalagata Timira* as in 1st *Patala* the vision becomes *Avyakta* which can be considered as blurred vision and in 2nd *Patala* the vision reduce further and patient sees the objects as if covered by cloud, *Makhsika Mashakan Pashyati* which can be taken as floaters. Risk factors and pathogenesis suggests involvement of *Pitta* and *Kapha dosha* mainly. *Pitta Kapha Shamaka* treatment was done in these cases of CSC. But the same time it should be ensure that *Vata Vridhhi* does not occur.

Shodhana Chikitsa:

Deepana Pachana with *Hingwashtaka Choorna* cures *Agnimandya*, thus improve *Jatharagni* and

Dhatwagni. Shodhana chikitsa play an important role in Ayurveda management which helps in eliminating all vitiated *Doshas* from the *Srotas*. For *Kaya Shodhana*, *Virechana* is the first choice in case of *Timira* as explained in *Ayurveda* classics; which showed significant effect in this condition as well. Patient felt *Sareera Laghavata* and *Indriya Pasannata* after completion of *Virechana* treatment with no complication.

Takradhara- *Takradhara* is widely used in the treatment of retinopathies [9]. Here in this condition deranged *Pitta* causes *Vilayana* of *Kapha* resulting in *shithilata* in the body and increase *Kleda*. *Takradhara* dose *Shoshana* of this excessive *Kleda* formed in the body thus balances *Kapha dosha*. When *Dhara* is dropped on the forehead near to the eyebrows, place of *Sthapani marma*. It provides more relief to the patient. Thus balance *Vata*.

Nasya-Nasya karma in indicated in several eye diseases as its eliminates *Dosas*. Medicine used in *Nasya* moves through the channels up to *Shringataka Marma*, and then spreads to whole of the *Shiras* and all *Srotas* of eye, ear and throat. *Shodhana Nasya* expel out all the accumulated *Kapha*. *Shamana nasya* pacifies the *Pitta dasa*.

Seka and Pindi - Skin is one of the routes of drug administration. The drug used in *Seka* and *Pindi* are *Yastimadhu*, *Ksheera*, *Saindhava*, *Triphala* cleanse the eye hence helps in removing localized *Aama*.

Tarpana - *Tarpana* procedure in posterior segment diseases of eye like CSC is of great importance as the major drug delivery to intra-ocular tissues occurs through the cornea to the aqueous humor and ciliary vessels. As retinal pigment epithelium is continued as the non-pigment epithelium of ciliary body, the drugs get absorbed through cornea may reach to the inner 3/4th retinal layers and outer 1/4th layers of retina gets from choroidal vessels from systemic route. Pre corneal drug retention, tissue contact time, molecular weight and size of the drug, lipophilicity of medicine affects the amount of drug permeation through the cornea. Drug availability in intraocular tissues increases due to longer duration of drug contact and, lipophilic and hydrophilic nature of drugs in medicated *Ghritas* in *Tarpana* procedure. Lipophilic drugs are better permeated through epithelium and endothelium and hydrophilic drugs are better penetrated through the stromal layer of cornea[10].

Limitation- Being a single case study the result cannot be generalized to the wider population.

CONCLUSION

Though CSC is self-limiting disease, treatment has to be done to protect gradual degeneration of photoreceptors and RPE which causes permanent

reduced vision. *Kaya Shodhana* followed by *Takradhara, Nasya, Seka, Pindi, Tarpana* with *Shamana Aushadhi* had shown significant improvement in Central Serous Choroidopathy. Completion of the treatment showed improves quality of vision. Foveal thickness and macular volume in OCT findings were reduced significantly. Thus Central Serous Choroidopathy can be treated with this line of treatment.

Scope for further study - In this case study the findings are valuable with effective treatment protocol. Thus further clinical trials on a larger set of samples would set a new trend in managing the condition efficiently.

REFERENCES

1. Semeraro F, Morescalchi F, Russo A, Gambicorti E, Pilotto A, Parmeggiani F, et al. Central Serous Choroidopathy: Pathogenesis and Management Clinical Ophthalmology. 2019; Volume 13:2341-52.
2. Liew G, Quin G, Gillies M, Fraser-Bell S. Central serous Choroidopathy: a review of epidemiology and pathophysiology. Clinical & Experimental Ophthalmology. 2012;41(2):201-14.
3. Sushruta, Acarya narayana Rama., Dalhana, Gayadasacarya. Sushrutasamhita. Acarya Yadavasharma Trivikrama, editor. Varanasi: Krshnadasa Akadamy 2008. Uttarantra. 7. 6-10
4. Sihota R, Tandon R. Central Serous Choroidopathy. In: Parsons ' diseases of the eye. 22nd ed. New Delhi: Elsevier; 2015
5. Kitzmann AS, Pulido JS, Diehl NN, Hodge DO, Burke JP. The incidence of Central Serous Choroidopathy in Olmsted county, Minnesota, 1980-2002. Ophthalmology. 2008;115(1):169-73.
6. Central Serous Retinopathy [Internet]. Retinal Physician. 2008 [cited 2020Apr19]. Available from: <https://www.retinalphysician.com/issues/2008/september-2008/central-serous-retinopathy>
7. Singh J. Kanji Water Preparation Method and Benefits [Internet]. Ayur Times. 2019 [cited 2020 Apr19]. Available from: <https://www.ayurtimes.com/kanji-water>
8. Shankar U. Central Serous Retinopathy. In: Text book of Shalaky Tantra, Illustrated: (according to Revised syllabus For BAMS course by Central Council of Indian Medicine, New Delhi) Varanasi: Chaukhambha Visvabharati; 2012. p. 644-55.
9. Shankar U. Central Serous Retinopathy. In: Text book of Shalaky Tantra, Illustrated: (according to Revised syllabus For BAMS course by Central Council of Indian Medicine, New Delhi). Varanasi: Chaukhambha Visvabharati; 2012. p. 175.
10. Sahoo PK, Fiaz S. Conceptual analysis of diabetic retinopathy in Ayurveda. Journal of Ayurveda and Integrative Medicine. 2017;8(2):122-31.

Cite this article as:

Meera Panigrahi, Naveen B S, Ajoy Viswam, Krishnan Namboodiri G. An Ayurveda Approach in the Management of Central Serous Choroidopathy - A Case Study. International Journal of Ayurveda and Pharma Research. 2021;9(Suppl 1):63-66. <https://doi.org/10.47070/ijapr.v9iSuppl1.2048>

Source of support: Nil, Conflict of interest: None Declared

*Address for correspondence

Dr. Meera Panigrahi

PG Scholar,

Department of Shalaky Tantra,
Sri Sri College of Ayurveda
Science and Research, Bangalore.

Email:

meeraabhimanyu@gmail.com

Disclaimer: IJAPR is solely owned by Mahadev Publications - dedicated to publish quality research, while every effort has been taken to verify the accuracy of the content published in our Journal. IJAPR cannot accept any responsibility or liability for the articles content which are published. The views expressed in articles by our contributing authors are not necessarily those of IJAPR editor or editorial board members.